

# Effect of using static ultrasound technique on peripherally inserted central catheters' insertion success rate in neonates in a neonatal intensive care unit

Zahra Abdeyazdan<sup>1</sup>, Elaheh Sheikhan-Sudani<sup>2</sup>, Alireza Sadeghnia<sup>3</sup>, Sedigheh Talakoub<sup>4</sup>

## ABSTRACT

**Background:** Peripheral insertion of central catheters can be difficult in neonates. We compared the success rates of peripherally inserted central catheters by two methods of using static ultrasound and traditional technique (vein visualization and palpation) in neonates.

**Materials and Methods:** In a prospective randomized, controlled trial, 52 neonates with birth weight lower than 1500 g in a level 3 neonatal intensive care unit were enrolled. Neonates were randomized to undergo peripherally inserted central catheter placement using a traditional technique ( $n = 27$ ) versus static ultrasound-guided technique ( $n = 25$ ). In the ultrasound group, vein localization was performed and the skin overlying the target vessel was marked. Insertion of catheter was then immediately performed. We recorded and compared success rates in the groups.

**Results:** Success rate after the first attempt was 68% in ultrasound group and 60% in traditional group. These rates for the second attempt were 50% and 40%, respectively. The overall success rates after two attempts were 84% and 76% in ultrasound and traditional groups, retrospectively ( $P = 0.24$ ).

**Conclusions:** There was no significant difference between the two groups regarding PICC success rates, probably because in the present study, most of the subjects were premature neonates whose vasculature was visually detectable.

**Key words:** Iran, neonatal intensive care unit, neonate, peripherally inserted central catheter, ultrasound

## INTRODUCTION

As the life and also growth and development of premature and ill neonates depend on total parenteral nutrition, intravenous fluid therapy, and antibiotics administration during hospitalization,<sup>[1]</sup> their intravascular access is a big challenge.<sup>[2]</sup>

Peripheral intravenous catheters are suggested for short-term intravenous treatments administered for less than 6 days, but infusion of irritant fluids should be avoided through

this method due to their possible damage.<sup>[3]</sup> Peripherally inserted central catheter (PICC) was first introduced in 1973 for severely diseased neonates. This method was known as an efficient way for administration of total intravenous nutrition in premature neonates.<sup>[4]</sup> PICC is a long soft and flexible catheter which is inserted to central veins through a peripheral vein. The tip of PICC, if inserted through upper limbs veins and skull veins, is placed in superior vena cava and near the right atrium, and if through lower limbs veins, in inferior vena cava and near the right atrium.<sup>[1,5,6]</sup> Centers for Disease Control and Prevention (2011) and also Infusion Nurses Society (2006) suggested that in cases wherein intravenous infusion is expected to last for more than 6 days, a PICC should be initially inserted. The factors known to be responsible for successful PICC insertion include early detection of PICC candidates, rapid and early insertion of a PICC by an experienced and skilled person, being knowledgeable of the vascular anatomy, and selection of the correct vein.<sup>[6]</sup> In addition, if the PICC is inserted prior to frequent trials for peripheral veins' venipuncture, the success rate is increased.<sup>[7]</sup> Now a day Over 5 million PICCs are inserted globally,<sup>[8]</sup> of which 3 million cases are in the US. About 70% of these catheters are inserted by nurses in the US.<sup>[9]</sup> In most of the health care centers, selection of veins for PICC is done either through observation or

<sup>1</sup>Department of Pediatric and Neonatal Nursing, Nursing and Midwifery Care Research Center, Faculty of Nursing and Midwifery, Isfahan University of Medical Sciences, Isfahan, Iran, <sup>2</sup>Student Research Committee, Faculty of Nursing and Midwifery, Isfahan University of Medical Sciences, Isfahan, Iran, <sup>3</sup>Department of Neonatology, School of Medicine, Isfahan University of Medical Sciences, Isfahan, Iran, <sup>4</sup>Department of Pediatric and Neonatal Nursing, Faculty of Nursing and Midwifery, Isfahan University of Medical Sciences, Isfahan, Iran

**Address for correspondence:** Dr. Alireza Sadeghnia, Department of Neonatology, School of Medicine, Isfahan University of Medical Sciences, Isfahan, Iran. E-mail: asadeghnia@gmail.com

Submitted: 14-Dec-13; Accepted: 06-Aug-14

touching the related vein,<sup>[10,11]</sup> while an assistive tool can increase the chances of success rate in PICC insertion in cases that the veins cannot be observed or touched or are already damaged.<sup>[2]</sup> One of these assistive tools is application of ultrasound to select the proper vein. It not only helps in the convenient detection of veins, arteries, and nerves in upper limbs, but also checks the features of the selected vein before venipuncture and assures the selection of the proper vein for PICC insertion.<sup>[12,13]</sup> with applying ultrasound for PICC insertion in adults by nurses in recent years, the insertion success rate notably increased, compared to the methods of direct vein visualization and palpation (traditional method) (90% vs. 60-80%). Studies showed that application of ultrasound by nurses led to success in PICC insertion in children and adults.<sup>[9,12,13]</sup> On the other hand, application of ultrasound images among neonates is notable as it contains no ionizing rays, is a non-invasive method, and causes no pain.<sup>[14]</sup> If application of ultrasound could lead to reduction of time for catheter insertion and the number of insertion attempts it can reduce pain in neonates,<sup>[14]</sup> so it will be efficient in preventing brain damage in growing neonates.<sup>[15]</sup> In Iran, insertion of PICC in neonates was begun in the neonatal intensive care units (NICUs) of hospitals affiliated to Isfahan University of Medical Sciences in the year 2010. In the beginning, the number of insertions was limited; but from 2012, applying PICC for vein access were increased, especially in premature neonates. Unfortunately there is no evidence concerning the number of insertions and the level of their success. In addition, selection of the related vein is done by nurses in these centers through direct vein visualization and palpation of the vein, like many other centers in the world,<sup>[11]</sup> and no assistive tool is used for PICC insertion.

The researchers found no studies concerning the success of PICC insertion through application of ultrasound among neonates. The success rate of PICC insertion may increase through application of ultrasound among neonates; but on the other hand, using an assistive tool in PICC application among the more premature neonates and those with lower weight who have thin skin and observable veins may be less helpful.<sup>[2]</sup> Therefore, the present study aimed to investigate the effect of using static ultrasound-guided technique on success rate of PICC insertion in neonates in an NICU.

## MATERIALS AND METHODS

This is a randomized clinical trial. After getting approval for the research project from the ethics committees of Alzahra hospital and Isfahan University of Medical Sciences, sampling was conducted during 2 months from June to November 2013 in the NICU of Alzahra hospital affiliated to Isfahan University of Medical Sciences. After obtaining

a written consent from the infants' parents, all candidates of PICC insertion with weight less than 1500 g and an intact antecubital area were randomly assigned to two groups of PICC insertion through ultrasound ( $n = 25$ ) and conventional ( $n = 25$ ) methods. In the control group, PICC insertion was performed by the conventional (routine) method through direct vein visualization and palpation of the vein. In the study group, before PICC insertion, subjects' antecubital areas of both upper limbs were investigated through static sonography, and PICC insertion was performed by a researcher who was familiar with this method and had a certificate for PICC insertion through sonography. Firstly, after target vein entrance localization on the device monitor, the overlying skin was marked by a marker. Next, the target point was disinfected and the primary needle was inserted in a place relatively lower than the marked point. Other stages and all equipments used in both groups were quite identical. In case of succeeding in each attempt, the catheter was fixed with an occlusive temporary dressing, and then, radiography was conducted to assure proper placement of the catheter tip. Then a neonatologist who was unaware about the insertion method confirmed the precise place of the catheter tip. If the first attempt on the antecubital area of one limb failed, the second attempt was made on the counterpart point in the other limb. If the second attempt also failed, PICC insertion was recorded unsuccessful, and catheter insertion was made for the neonates in other veins to fulfill their needs. PICC used in the present research was manufactured by Vygon Company, in Germany and was made of polyurethane in French sizes of one and two. Intervention tool in the present study was an ultrasound device (Signous) with a 3.5 MHz transducer, made in Australia. Demographic data of the neonates were collected from their medical records and were analyzed by SPSS version 18. Chi-square test and independent *t*-test were used to compare the qualitative and quantitative variables, respectively.

## RESULTS

Out of 52 neonates entering the study, 2 infants in the study group were initially excluded as the veins located in the antecubital area could not be observed with ultrasound [Figure 1]. Table 1 presents the demographic characteristics of the two groups. Independent *t*-test showed no significant difference in subjects' demographic characteristics. The obtained data showed that the mean gestational age of the subjects was 29.49 weeks, ranging between 27 and 38 weeks, and their mean birth weight was 1147.40 g (range 720–1500 g) [Table 1]. Table 2 presents the success rates of PICC insertion in the two groups. The first PICC insertion attempts were successful for 17 neonates out of 25 (68%) in ultrasound method and for 15 out of 25

**Table 1: Comparison of baseline characteristics of subjects in the two methods of PICC insertion**

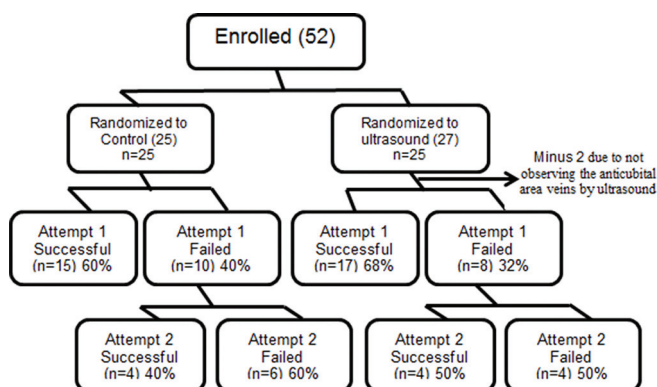
Insertion method Variable	Ultrasound		Conventional		Independent t-test	
	Mean (SD)	Min.-Max.	Mean (SD)	Min.-Max.	t	P value
Gestational age (weeks)	29.2 (1.9)	27-34	29.8 (3.1)	27-38	0.740	0.463
Age at insertion time (days)	2.9 (2.8)	0-11	3.9 (6.9)	0-25	0.7	0.49
Birth weight (g)	1131.6 (209.4)	800-1490	1163.2 (272.9)	720-1500	0.46	0.648
Birth weight at insertion time	1130 (208.7)	800-1490	1178.4 (274.1)	720-1500	0.7	0.486

PICC: Peripherally inserted central catheter, SD: Standard deviation

**Table 2: Comparison of relative frequency of PICC insertion and success rate in the first and second attempts**

Insertion method Trial number	Ultrasound			Conventional			$\chi^2$ test result	
	Successful	Unsuccessful	Total	Successful	Unsuccessful	Total	$\chi^2$	P value
	Number (%)	Number (%)		Number (%)	Number (%)			
First attempt	17 (68)	8 (32)	25	15 (60)	10 (40)	25	0.347	0.28
Second attempt	4 (50)	4 (50)	8	4 (40)	6 (60)	10	-	0.52f
Overall success after two attempts	21 (84)	4 (16)	25	19 (76)	6 (24)	25	0.5	0.24

PICC: Peripherally inserted central catheter

**Figure 1:** Flow diagram of patients through PICC placement attempts by group

neonates (60%) in conventional method, which showed no significant difference. Of the eight unsuccessful PICC insertion cases in the first attempt through ultrasound method, the second attempt was successful in four neonates (40%), but the difference was not significant. Overall, the PICC insertion success rates after two insertion attempts were 84% in ultrasound method and 76% in conventional method. Although the success rate in ultrasound method was higher, the difference was not significant.

## DISCUSSION

Results showed that the PICC insertion success rate in neonates through ultrasound method was more than in conventional method (84% vs. 76%), but the difference was not significant. Most of the previous studies have investigated the effect of ultrasound application on PICC insertion success rates in adults and children. Johnson *et al.* (2009) reported an increase from 88 to 94% in PICC

insertion success rate after applying portable ultrasound in their center (2003), and the success rate reached 98% in 2007. Other studies showed a significant increase in PICC insertion success rate through ultrasound method compared to conventional method. For instance, Carvalho *et al.* (2012) investigated PICC insertion success rate through ultrasound method in 69 children less than 18 years of age and reported a significant increase in PICC insertion for the first attempt, in ultrasound method ( $P = 0.003$ ).<sup>[13]</sup> The reason for the difference observed in our results from those of previous researches could be that most of the neonates in the present study were premature or very low birth weight, and their veins were clearly observable.<sup>[2,13]</sup> Therefore, it seems that the results would possibly be different if the research is conducted on term neonates. However, conducting further studies is essential. On the other hand, concerning the difficult intravenous access, as determined by Difficult Intravenous Access (DIVA) score,<sup>[16]</sup> and consideration of scores over 4 for this categorization in neonates, and as all the subjects were premature with observable veins in the present study, the scores obtained with this tool should be calculated as 3 due to the subjects' clearly observable veins and these subjects should not be categorized in DIVA group. In addition, in the present study, the researcher used the only available static ultrasound device in research environment to insert PICC. Therefore, the device was just used to detect the veins, but the catheter conduction was performed similar to the conventional method practiced in the ward, this can be another reason for the insignificant difference obtained in PICC insertion success rates in these two methods. Bear *et al.* applied the same method to insert PICC in children less than 7 years of age with difficult vascular access and obtained similar results.<sup>[17]</sup> In the present study, the two groups had no

significant difference in the location of PICC insertion, and in both groups, the vein that was mostly used for insertion was right basilica vein. The reason could be that as superior vena cava is on the right side of sternum and the pathway of insertion from right basilica toward superior vena cava is more direct and shorter, although both right and left basilica veins were observable, the insertion into right basilica vein was given the priority, and just in cases of failure, the left basilica vein was used for the second attempt.

At the present study the researcher responsible to insert PICC was aware of the ongoing study and placement of subjects in the study or the control group. So it can be counted as a limitation in the present study, however to reduce bias in the results, the X-rays were handed to a pediatric sub-specialist who was blinded to group allocation at the time of announcing the success or failure of PICC insertion.

## CONCLUSION

Although the effect of using static ultrasound on success rate of first attempt PICC insertion has been approved in adults and children in previous studies, but based on the experience of the researchers of the present study after sampling, it seems that as premature neonates' veins are clearly observable, application of static ultrasound is not so beneficial to them. However, because application of ultrasound in PICC insertion can help to insert the catheter into the correct pathway, toward vena cava, or in placing the catheter tip in superior vena cava, simultaneously with insertion and before fixation in its location, or determination of vein diameter, and selection of a proper vein with a proper size, the authorities of NICUs are suggested to design professional educational programs to educate PICC insertion team concerning application of ultrasound method.

## ACKNOWLEDGMENTS

This article is extracted from dissertation no. 392150, sponsored by Vice Chancellor in Isfahan University of Medical Sciences. The authors express their appreciation to the Vice Chancellor for of Isfahan University of Medical Sciences for financial support, the head nurse of NICU in Alzahra hospital in Isfahan, and all personnel and neonates' parents for cooperating with the research. They also acknowledge Dr. Zohre Badiie, the head of neonatology department of the medical school, for facilitation of this research.

## REFERENCES

- Pettit J, Wyckoff MM. Peripherally inserted central catheters. Guideline for Practice. 2<sup>nd</sup> ed. Glenview: National Association of Neonatal Nurses; 2007. Available from <http://www.nann.org/pdf/PICCGuidelines.pdf>. [Last accessed on 2013 Aug 10].
- Phipps K, Modic A, O'Riordan M, Walsh M. A randomized trial of the Vein Viewer versus standard technique for placement of peripherally inserted central catheters (PICCs) in neonates. *J Perinatol* 2011;32:498-501.
- Heiss-Harris GM, Bailey T. 'Common invasive procedures' in Core Curriculum for Neonatal Invasive Care Nursing. In: Verklan MT, Walden M, editors. Missouri: St. Louise Saunders Elsevier; 2010.
- Barriá RM, Lorca P, Muñoz S. Randomized controlled trial of vascular access in newborns in the neonatal intensive care unit. *J Obstet Gynecol Neonatal Nurs* 2007;36:450-6.
- O'Grady N, Alexander, M, Burns, LA, Dellinger, EP, Garland, J, Heard, *et al.* The Healthcare Infection Control Practices Advisory Committee (HICPAC), Guidelines for the prevention of intravascular catheter-related infections. Centers for Disease Control and Prevention (CDC). 2011, Available from: <http://www.cdc.gov/hicpac/bsi/bsi-guidelines-2011>. [Last accessed on 2013 Aug 12].
- Paulson PR, Miller KM. Neonatal peripherally inserted central catheters: Recommendations for prevention of insertion and post insertion complications. *Neonatal Netw* 2008;27:245-57.
- MacDonald MR J. Atlas of procedures in neonatology. Washington, DC: Lippincott Williams and Wilkins; 2007.
- Moureau N. Preventing PICC complications: Whose line is it? USA: U.S. Department of Health and Human Services; 2012. Available from: <http://www.webmm.ahrq.gov/case.aspx?caseID=289> [Last accessed on 2013 Apr 28].
- AIUM Practice Guideline for the Use of Ultrasound to Guide Vascular Access Procedures. *J Ultrasound Med* 2013;32:191-215.
- Moureau N. Neonatal and pediatric peripherally inserted central catheters: Basic manual. Ecouen-france: VYGON Corporation; 2005.
- Sharpe E, Pettit J, Ellsbury DL. A national survey of neonatal peripherally inserted central catheter (PICC) practices. *Adv Neonatal Care* 2013;13:55-74.
- Moureau NL. Using ultrasound to guide PICC and peripheral cannula insertion. *Nursing* 2008;38:20-1.
- de Carvalho Onofre PS, da Luz Gonçalves Pedreira M, Peterlini MA. Placement of peripherally inserted central catheters in children guided by ultrasound: A prospective randomized, and controlled trial. *Pediatr Crit Care Med* 2012;13:1-6.
- Doniger SJ, Ishimine P, Fox JC, Kanegaye JT. Randomized controlled trial of ultrasound-guided peripheral intravenous catheter placement versus traditional techniques in difficult-access pediatric patients. *Pediatr Emerg Care* 2009;25:154-9.
- Fidler HL. The use of bedside ultrasonography for PICC placement and insertion. *Adv Neonatal Care* 2011;11:52-3.
- Yen K, Riegert A, Gorelick MH. Derivation of the DIVA score: A clinical prediction rule for the identification of children with difficult intravenous access. *Pediatr Emerg Care* 2008;24:143-7.
- Bair AE, Rose JS, Vance CW, Andrada-Brown E, Kuppermann N. Ultrasound-Assisted Peripheral Venous Access In Young Children: A Randomized Controlled Trial And Pilot Feasibility Study. *West J Emerg Med* 2008;9:219-24.

**How to site:** Abdeyazdan Z, Sheikhan-Sudani E, Sadeghnia A, Talakoub S. Effect of using static ultrasound technique on peripherally inserted central catheters' insertion success rate in neonates in a neonatal intensive care unit. *Iranian Journal of Nursing and Midwifery Research* 2014;19:643-6.

**Source of Support:** Isfahan University of Medical Sciences, **Conflict of Interest:** None declared.